

- transcriptional profiling to improve personalized diagnosis and management of cutaneous T-cell lymphoma (CTCL). *Clin Cancer Res* 2015;21:2820–9.
- Marzec M, Halasa K, Kasprzycka M, Wysocka M, Liu X, Tobias JW, et al. Differential effects of interleukin-2 and interleukin-15 versus interleukin-21 on CD4+ cutaneous T-cell lymphoma cells. *Cancer Res* 2008;68:1083–91.
- Platanias LC. Map kinase signaling pathways and hematologic malignancies. *Blood* 2003;101:4667–79.
- Sommer VH, Clemmensen OJ, Nielsen O, Wasik M, Lovato P, Brender C, et al. In vivo activation of STAT3 in cutaneous T-cell lymphoma. Evidence for an antiapoptotic function of STAT3. *Leukemia* 2004;18:1288–95.
- Sondergaard H, Frederiksen KS, Thygesen P, Galsgaard ED, Skak K, Kristjansen PE, et al. Interleukin 21 therapy increases the density of tumor infiltrating CD8+ T cells and inhibits the growth of syngeneic tumors. *Cancer Immunol Immunother* 2007;56:1417–28.
- Spolski R, Leonard WJ. Interleukin-21: a double-edged sword with therapeutic potential. *Nat Rev Drug Discov* 2014;13:379–95.
- van der Fits L, Out-Luiting JJ, Tensen CP, Zoutman WH, Vermeer MH. Exploring the IL-21-STAT3 axis as therapeutic target for Sezary syndrome. *J Invest Dermatol* 2014;134:2639–47.
- van der Fits L, Out-Luiting JJ, van Leeuwen MA, Samsom JN, Willemze R, Tensen CP, et al. Autocrine IL-21 stimulation is involved in the maintenance of constitutive STAT3 activation in Sezary syndrome. *J Invest Dermatol* 2012;132:440–7.
- Zhang X, Blenis J, Li HC, Schindler C, Chen-Kiang S. Requirement of serine phosphorylation for formation of STAT-promoter complexes. *Science* 1995;267:1990–4.

# A Distinct Genotype of XP Complementation Group A: Surprisingly Mild Phenotype Highly Prevalent in Northern India/Pakistan/Afghanistan



*Journal of Investigative Dermatology* (2016) 136, 869–872; doi:10.1016/j.jid.2015.12.031

Xeroderma pigmentosum (XP) is a rare inherited disorder of DNA repair. Affected individuals cannot repair ultraviolet radiation (UVR)–induced DNA damage, resulting in an increased skin cancer risk (Bradford et al., 2011), severe sunburn in approximately 50% of patients (Sethi et al., 2013), and progressive neurodegeneration in approximately 30% (Kraemer et al., 1987; Totonchy et al., 2013). XP can result from defects in any of eight genes (*XPA*–*XPG* and *POLH*). *XPA*–*XPG* are involved in nucleotide excision repair (NER) of DNA damage (Cleaver et al., 2009).

Xeroderma pigmentosum complementation group A (XP-A) patients usually have a severe phenotype, with exaggerated sunburn and early onset of progressive neurodegeneration, which results in death, usually in the second or third decade (Anttinen et al., 2008). XPA protein is required for damage verification in the NER pathway. More than 20 different mutations have been identified in the *XPA* gene (States et al., 1998; Takahashi et al., 2010). Many of the reported

cases come from Japan because of a founder mutation (c.390-1G>C) carried by 1% of the Japanese population (Hirai et al., 2006; Satokata et al., 1990). This mutation results in abnormal splicing of mRNA and subsequent production of truncated, nonfunctioning XPA protein and the typically severe clinical phenotype.

Although a diagnosis of XP-A has usually been associated with a poor prognosis, a number of XP-A patients undergoing long-term follow-up at the UK National XP Clinic have a surprisingly mild phenotype. To examine this finding further, a detailed genotype-phenotype study in this cohort was conducted. Neurological analysis included audiometry, nerve conduction studies, brain magnetic resonance imaging and neuropsychometric evaluations. Informed written consent was obtained from all patients. The study was performed in accordance with protocols approved by the Research Ethics Committee of Guy's and St. Thomas' Hospitals NHS Foundation Trust, London (reference 12/LO/0325).

Nineteen of 90 patients being studied at the UK National XP clinic were assigned to complementation group A (Table 1). Twelve of these patients, from eight consanguineous families, displayed a mild XP-A phenotype with no ocular surface disease, delayed onset or lack of skin cancer, and normal neurological and neuropsychometric evaluations (Figure 1a–h). Mean age at assessment was 32 years (range 6–79 years) and mean age at clinical diagnosis was 26 years (range 4–46 years), significantly higher than in the more severely affected XP-A group of patients, who showed progressive neurodegeneration presenting as developmental delay and cognitive impairment, sensorineural hearing loss, microcephaly, neuropathy, and cerebellar signs (Table 1). Remarkably, one of the patients, XP1CB, is aged 79 years without any XP-related neurological problems. He spent the first 30 years of his life in India working mostly outdoors and was only diagnosed clinically at age 46 years. These 12 patients all were homozygous for the mutation c.555+8A>G, which previously was reported by Sidwell et al. (2006) in a 61-year-old Punjabi woman with no neurological problems. All 12 patients included in this study, as well as the case described by Sidwell et al., originate from a 950-km stretch of land

Abbreviations: NER, nucleotide excision repair; UVR, ultraviolet radiation; XP, xeroderma pigmentosum; XP-A, xeroderma pigmentosum complementation group A

Accepted manuscript published online 29 December 2015; corrected proof published online 12 February 2016

© 2015 The Authors. Published by Elsevier, Inc. on behalf of the Society for Investigative Dermatology.

**Table 1. Summary of clinical features in the XP-A patient cohort**

XP number	Age (sex)	Country of origin	Age at clinical diagnosis	Cutaneous features	SSS	Developmental/neuropsychometric, and neurological evaluation	Age at first mucocutaneous cancer (type)	Mutation in XPA gene
XP9BI	6 (F)	Pakistan	6	Lentigines	0	Normal		c.555+8A>G
XP103BR	7 (F)	Pakistan	4	Lentigines	0	Normal		c.555+8A>G
XP53BR	18 (M)	Pakistan	7	Lentigines/photosensitivity	1	Normal		c.555+8A>G
XP121BR	25 (F)	Pakistan	25	Lentigines	1	Normal		c.555+8A>G
XP116BR	31 (M)	India	31	Lentigines	1	Normal	31 (BCC)	c.555+8A>G
XP2PR	32 (F)	Pakistan	32	Lentigines	1	Normal		c.555+8A>G
XP89BR-S	34 (M)	Pakistan	33	Lentigines	2	Normal		c.555+8A>G
XP1PR	35 (M)	Pakistan	35	Lentigines	2	Normal		c.555+8A>G
XP88BR	36 (M)	Pakistan	31	Lentigines	3	Normal		c.555+8A>G
XP49BR	38 (M)	Afghanistan	24	Lentigines/photosensitivity	1	Normal		c.555+8A>G
XP89BR	43 (F)	Pakistan	39	Photosensitivity	3	Normal		c.555+8A>G
XP1CB	79 (M)	India	46	Lentigines	0	Normal	46 (MM)	c.555+8A>G
XP111BR	7 (F)	Bangladesh	5	Lentigines	3	Abnormal		c.253C>T p.(Gln85TER)
XP57BR	14 (F)	Bangladesh	1	Photosensitivity	1	Abnormal		c.640dupA p.(Met214fs)
XP80BR	14 (F)	Somalia	8	Photosensitivity	3	Abnormal		c.314G>A p.(Cys105Tyr)
XP81BR	18 (M)	Somalia	12	Photosensitivity	1	Abnormal		c.314G>A p.(Cys105Tyr)
XP15BR	22 (M)	UK	0.5	Photosensitivity	3	Abnormal		c.266_267dupAA p.(Val90fs)
XP114BR	24 (M)	Pakistan	22	Photosensitivity	3	Abnormal	22 (SCC)	c.682C>T p.(Arg228TER)
XP20BR	32 (M)	Pakistan	13	Photosensitivity	3	Abnormal	22 (ocular CIN3)	c.682C>T p.(Arg228TER)

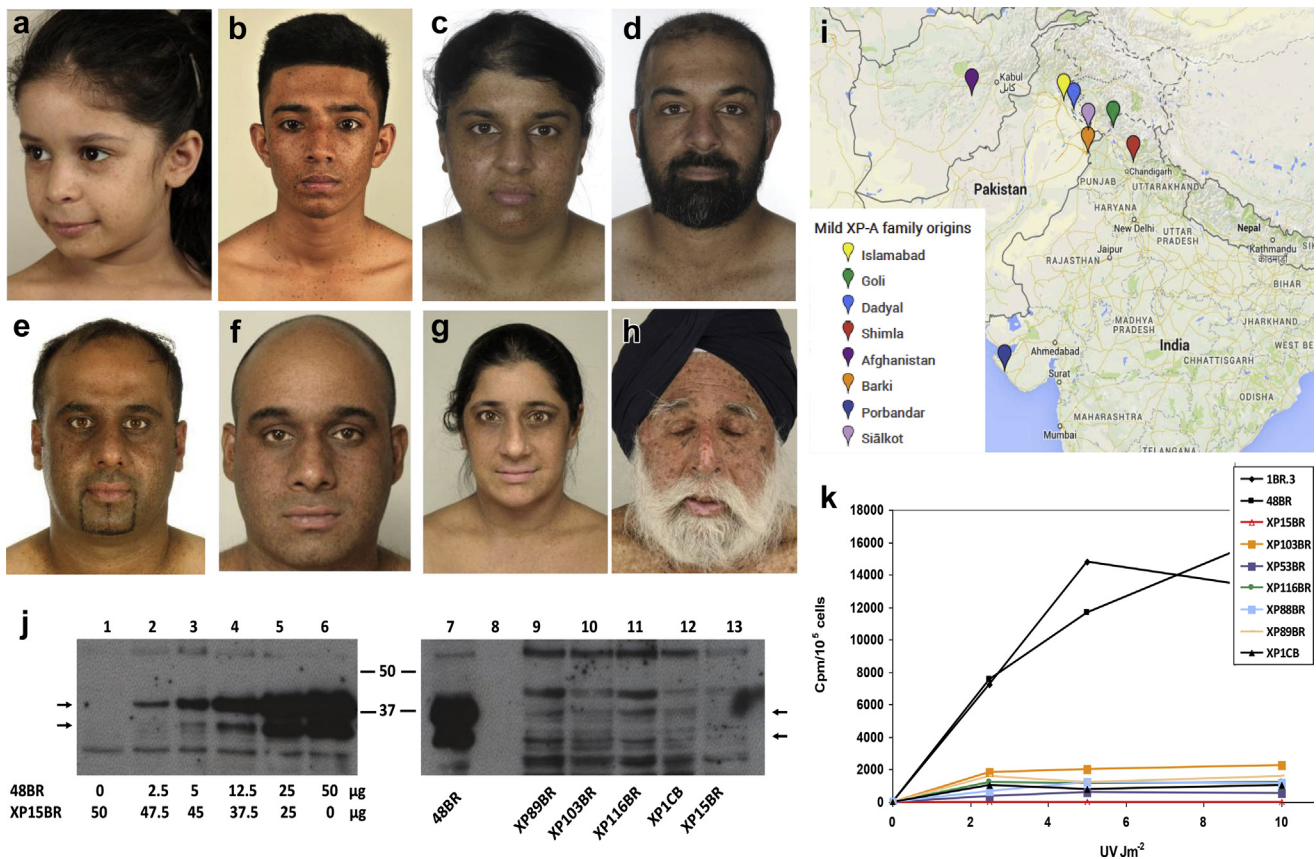
Abbreviations: BCC, basal cell carcinoma; CIN, conjunctival intraepithelial neoplasia; F, female; M, male; MM, malignant melanoma; SCC, squamous cell carcinoma; SSS, sunburn severity score (Sethi et al., 2013); XP, xeroderma pigmentosum; XP-A, xeroderma pigmentosum complementation group A.

around the Northern India/Pakistan/Afghanistan borders (Figure 1i), suggesting a founder effect present in this population.

The c.555+8A>G mutation at the eighth nucleotide of intron 4 generates a new splice donor site and results in aberrant splicing of intron 4 and nonfunctional, truncated XPA protein. However, there is a small amount of normally spliced mRNA (Sidwell et al., 2006), which results in production of residual normal XPA protein detectable in immunoblots (Figure 1j). Comparison of the upper XPA band in lanes 9–12 with the calibration in lanes 1–6 suggests that 50-µg extract from the mild XP-A cells has the same amount of (or less) XPA protein as 2.5-µg normal extract (lane 2), indicating the presence of <5% of the normal level of XPA protein in the mild XP-A cells. In contrast, no protein is detectable in the XP-A null cell line XP15BR (lanes 1 and 13). This residual protein carries out NER, consistent with the 5–15% of normal unscheduled DNA synthesis found in these patients (Figure 1k). This most likely explains their normal neurological phenotype. It has been shown that low levels of XPA protein, transfected into XPA-deficient cells, are able to significantly protect against DNA damage (Muotri et al., 2002).

Interestingly, the sunburn reactions in this group are variable, even though all patients are of similar ethnicity. This may be explained by the fact that the very small amount of functioning XPA protein may not be sufficient to repair the high level of photoproduct accumulation after sun exposure, resulting in moderate sunburn severity. However, endogenous neurological damage is likely to be generated continually at a low rate so that the low level of functioning XPA protein may be sufficient to repair the damage as it occurs, resulting in a normal neurological phenotype.

A handful of other XP-A patients with mild phenotype have been reported in the literature, although none as mild as our cohort. Four middle-aged Japanese XP-A patients presented with late-onset neurological impairment and moderate sunburn reactions, without development of skin cancer (Takahashi et al.,



**Figure 1.** Face views of mild xeroderma pigmentosum complementation group A (XP-A) patients and map of origins, immunoblots of protein extracts probed with monoclonal antibody to XPA protein, and measurement of UDS in mild XP-A and control cell lines. (a) XP103BR: Seven-year-old girl with a few facial lentigines (distantly related to patients shown in e–g). (b) XP53BR: Eighteen-year-old man who presented with sunburn lasting 1 week and increased lentigines at exposed sites. (c, d) XP2PR, XP1PR: Two siblings aged 32 and 35 years, respectively, who developed facial lentigines at age 2 years (distantly related to patients shown in e–g). (e–g) XP89BR-S, XP88BR, XP89BR: Three siblings, currently aged 34, 36, and 43 years, respectively, who presented with increased facial lentigines and easy sunburn. (h) XP1CB: Seventy-nine-year-old man who developed lentigines at exposed sites at age 6 years. Of the seven other siblings in his family, four have XP. Until 30 years of age he had worked outdoors as a veterinarian in India, with high cumulative ultraviolet radiation exposure. He then moved to the United Kingdom and worked indoors as a pathologist until his retirement. He developed melanoma in situ on his left cheek at age 46 years and since then has developed 8 melanomas and >20 nonmelanoma skin cancers. He underwent a left hemicolectomy for a sigmoid colon adenocarcinoma Dukes B at age 55 years, followed by further surgery for mucinous adenocarcinoma Dukes B2 the following year. He subsequently developed keratoacanthomas and a sebaceous adenoma, leading to a diagnosis of Muir-Torre syndrome [mutation c.306G>T in *MLH-1* (Thompson et al., 2014)] unrelated to his mutation in the *XPA* gene. (i) Origins of the eight families with mild XP-A are indicated on the map. (j) Immunoblots of protein extracts probed with monoclonal antibody to XPA protein (BD Bioscience, Oxford, UK, #556453). Left: Calibration: The 50- $\mu$ g protein extract is made up of the indicated quantities from normal 48BR cells and XPA-null XP15BR cells. Right: The 50  $\mu$ g of extract from the indicated cells. The positions of the 50-kDa and 37-kDa markers are indicated between the panels. XPA protein, indicated with arrows, runs as two bands on either side of the 37-kDa marker. Normal XPA protein level of  $\leq 5\%$  is detected in the mild XP-A cases but not in XP15BR. (k) UDS measured by incorporation of  $^3\text{H}$ -thymidine into nondividing cells after ultraviolet-C irradiation with the indicated doses. From 5% to 15% of normal UDS is detected in cells from the mild XP-A patients but is undetectable in XP15BR. UDS, unscheduled DNA synthesis. All patients pictured here have provided written and oral consent for publication of these photographs.

2010). Their milder phenotype was attributed to frameshift mutations in exon 6 [c.689dupT p.(Arg231fs) in one patient and c.779delCinsTTCTT p.(Thr260fs) in the other three] resulting in truncated XPA proteins.

This study highlights the importance of genotype-phenotype correlations in XP, not only for diagnosis but also for prognosis and genetic counseling. Here we present 12 XP-A patients with variable sunburn reactions and normal cognitive and neurological

phenotype, the largest number of mild XP-A patients reported to date. Although the milder skin phenotype may be related to some extent to the more pigmented Fitzpatrick skin types, in our cohort of patients, homozygous for c.555+8A>G, we are now able to give cautiously optimistic prognostic information with regard to lack of neurodegeneration and later onset of skin cancer. A diagnosis of mild XP-A should be considered in individuals with facial lentigines, originating from

the borders of Northern India, Pakistan, and Afghanistan, as early photoprotection can reduce further development of lentigines and potential skin cancers. Our findings from a relatively small immigrant population in the United Kingdom imply that there may be many such individuals in the area of origin, who are likely to be undiagnosed because of the mildness of symptoms and who may suffer from excessive skin damage later in life.



## CONFLICT OF INTEREST

The authors state no conflict of interest.

## ACKNOWLEDGMENTS

The National Multidisciplinary XP Clinic in the United Kingdom is funded by NHS England Highly Specialised Services. We thank Emma Craythorne (Consultant Dermatological Surgeon), Susie Morley (Consultant Ophthalmologist), Soji Abiona (Consultant Paediatrician), Isabel Garrod (Clinical Neuropsychologist), Paola Giunti (Consultant Neurologist), and Tammy Hedderly (Consultant Paediatric Neurologist) for clinical evaluation of the XP patients. We also thank Tom Callup for help in setting up the sequencing platform. This work was also supported by Medical Research Council (Fellowship Grant No. MR/M001210/1 to MS), the British Skin Foundation (Innovative Project Award Grant No. 5042i to HF), and the UK National Institute for Health Research (NIHR) Biomedical Research Centre based at Guy's and St. Thomas' NHS Foundation Trust and King's College London.

**Mieran Sethi<sup>1,2</sup>, Shaheen Haque<sup>3</sup>, Heather Fawcett<sup>4</sup>, Jonathan F. Wing<sup>4</sup>, Natalie Chandler<sup>5</sup>, Shehla Mohammed<sup>5</sup>, Ian M. Frayling<sup>6</sup>, Paul G. Norris<sup>3</sup>, David McGibbon<sup>2</sup>, Antony R. Young<sup>1</sup>, Robert P.E. Sarkany<sup>2</sup>, Alan R. Lehmann<sup>4</sup> and Hiva Fassihi<sup>2,\*</sup>**

<sup>1</sup>King's College London, Kings Health Partners, Division of Genetics and Molecular Medicine, St. John's Institute of Dermatology, Guy's Hospital, London, United Kingdom; <sup>2</sup>National Xeroderma Pigmentosum Service, Department of Photodermatology, St. John's Institute of Dermatology, Guy's and St. Thomas' NHS Foundation Trust, London, United Kingdom; <sup>3</sup>Department of

Dermatology, Addenbrooke's Hospital, Cambridge University Hospitals NHS Foundation Trust, Cambridge, United Kingdom; <sup>4</sup>Genome Damage and Stability Centre, University of Sussex, Falmer, Brighton, United Kingdom; <sup>5</sup>Genetics Department, Guy's and St. Thomas' NHS Foundation Trust, London, United Kingdom; and <sup>6</sup>Institute of Medical Genetics, University Hospital of Wales, Cardiff, United Kingdom \*Corresponding author e-mail: hiva.fassihi@gstt.nhs.uk

## REFERENCES

- Anttinen A, Koulu L, Nikoskelainen E, Portin R, Kurki T, Erkinjuntti M, et al. Neurological symptoms and natural course of xeroderma pigmentosum. *Brain* 2008;131(Pt 8):1979–89.
- Bradford PT, Goldstein AM, Tamura D, Khan SG, Ueda T, Boyle J, et al. Cancer and neurologic degeneration in xeroderma pigmentosum: long term follow-up characterises the role of DNA repair. *J Med Genet* 2011;48:168–76.
- Cleaver JE, Lam ET, Revet I. Disorders of nucleotide excision repair: the genetic and molecular basis of heterogeneity. *Nat Rev Genet* 2009;10:756–68.
- Hirai Y, Kodama Y, Moriwaki S, Noda A, Cullings HM, Macphee DG, et al. Heterozygous individuals bearing a founder mutation in the XPA DNA repair gene comprise nearly 1% of the Japanese population. *Mutat Res* 2006;10(601):171–8.
- Kraemer KH, Lee MM, Scotto J. Xeroderma pigmentosum. Cutaneous, ocular, and neurologic abnormalities in 830 published cases. *Arch Dermatol* 1987;123:241–50.
- Muotri AR, Marchetto MC, Suzuki MF, Okazaki K, Lotfi CF, Brumatti G, et al. Low amounts of the DNA repair XPA protein are sufficient

to recover UV-resistance. *Carcinogenesis* 2002;23:1039–46.

- Satokata I, Tanaka K, Miura N, Miyamoto I, Satoh Y, Kondo S, et al. Characterization of a splicing mutation in group A xeroderma pigmentosum. *Proc Natl Acad Sci U S A* 1990;87:9908–12.
- Sethi M, Lehmann AR, Fawcett H, Stefanini M, Jaspers N, Mullard K, et al. Patients with xeroderma pigmentosum complementation groups C, E and V do not have abnormal sunburn reactions. *Br J Dermatol* 2013;169:1279–87.
- Sidwell RU, Sandison A, Wing J, Fawcett H, Seet JE, Fisher C, et al. A novel mutation in the XPA gene associated with unusually mild clinical features in a patient who developed a spindle cell melanoma. *Br J Dermatol* 2006;155:81–8.
- States JC, McDuffie ER, Myrand SP, McDowell M, Cleaver JE. Distribution of mutations in the human xeroderma pigmentosum group A gene and their relationships to the functional regions of the DNA damage recognition protein. *Hum Mutat* 1998;12:103–13.
- Takahashi Y, Endo Y, Sugiyama Y, Inoue S, Iijima M, Tomita Y, et al. XPA gene mutations resulting in subtle truncation of protein in xeroderma pigmentosum group A patients with mild skin symptoms. *J Invest Dermatol* 2010;130:2481–8.
- Thompson BA, Spurdle AB, Plazzer JP, Greenblatt MS, Akagi K, Al-Mulla F, et al. Application of a 5-tiered scheme for standardized classification of 2,360 unique mismatch repair gene variants in the InSiGHT locus-specific database. *Nat Genet* 2014;46:107–15.
- Totonchy MB, Tamura D, Pantell MS, Zalewski C, Bradford PT, Merchant SN, et al. Auditory analysis of xeroderma pigmentosum 1971–2012: hearing function, sun sensitivity and DNA repair predict neurological degeneration. *Brain* 2013;136(Pt 1):194–208.

See related commentary on pg 742

# Meganuclease-Mediated COL7A1 Gene Correction for Recessive Dystrophic Epidermolysis Bullosa



*Journal of Investigative Dermatology* (2016) 136, 872–875; doi:10.1016/j.jid.2015.11.028

## TO THE EDITOR

Dystrophic epidermolysis bullosa (DEB) is a rare and severe genetic skin disease inherited in a dominant (DDEB) or recessive (RDEB) manner, responsible for blistering of the skin and mucosa

after mild trauma (Bruckner-Tuderman, 2010; Uitto et al., 1992). DEB is caused by a wide variety of mutations in COL7A1 encoding type VII collagen, the major component of anchoring fibrils which form key attachment

structures for dermal-epidermal adhesion (Hovnanian et al., 1997; Varki et al., 2007).

Gene correction approaches based on sequence-specific DNA double strand breaks (DSB)-mediated homology-directed repair (HDR) allow precise and accurate correction of mutations (Yanez-Munoz et al., 2006). They have the potential to restore stable expression and function of the defective gene and to reverse the disease phenotype

Abbreviations: DDEB, dominant dystrophic epidermolysis bullosa; DSB, double strand breaks; HDR, homology-directed repair; IDLVs, integration-deficient lentiviral vectors; MNs, meganucleases; RDEB, recessive dystrophic epidermolysis bullosa

Corrected proof published online 17 February 2016

© 2016 The Authors. Published by Elsevier, Inc. on behalf of the Society for Investigative Dermatology.