

Online Research @ Cardiff

This is an Open Access document downloaded from ORCA, Cardiff University's institutional repository: <http://orca.cf.ac.uk/112244/>

This is the author's version of a work that was submitted to / accepted for publication.

Citation for final published version:

Hurley, Joanna J., Thomas, Laura E., Walton, Sarah-Jane, Thomas-Gibson, Siwan, Haycock, Adam, Suzuki, Noriko, Mort, Matthew, Williams, Geraint, Morgan, Meleri, Clark, Susan K., Sampson, Julian R. and Dolwani, Sunil 2018. The impact of chromoendoscopy for surveillance of the duodenum in patients with MUTYH-associated polyposis and familial adenomatous polyposis. *Gastrointestinal Endoscopy* 88 (4) , pp. 665-673. 10.1016/j.gie.2018.04.2347 file

Publishers page: <http://dx.doi.org/10.1016/j.gie.2018.04.2347>
<<http://dx.doi.org/10.1016/j.gie.2018.04.2347>>

Please note:

Changes made as a result of publishing processes such as copy-editing, formatting and page numbers may not be reflected in this version. For the definitive version of this publication, please refer to the published source. You are advised to consult the publisher's version if you wish to cite this paper.

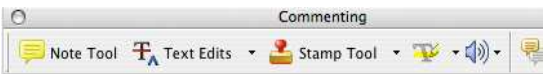
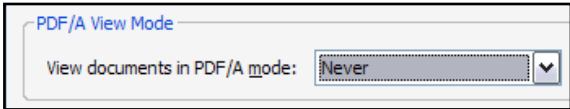

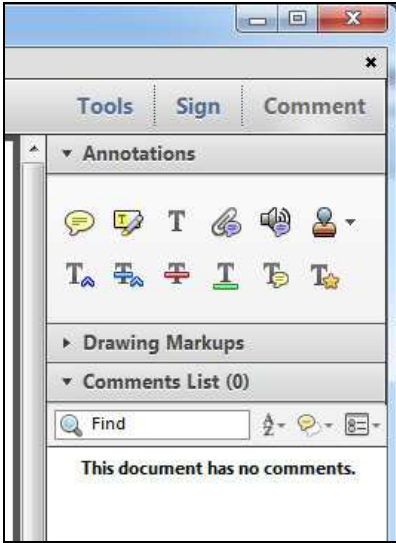
This version is being made available in accordance with publisher policies. See <http://orca.cf.ac.uk/policies.html> for usage policies. Copyright and moral rights for publications made available in ORCA are retained by the copyright holders.



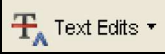


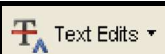

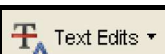







INSTRUCTIONS ON THE ANNOTATION OF PDF FILES


To view, print and annotate your content you will need Adobe Reader version 9 (or higher). This program is freely available for a whole series of platforms that include PC, Mac, and UNIX and can be downloaded from <http://get.adobe.com/reader/>. The exact system requirements are given at the Adobe site: <http://www.adobe.com/products/reader/tech-specs.html>.

Note: Please do NOT make direct edits to the PDF using the editing tools as doing so could lead us to overlook your desired changes. Rather, please request corrections by using the tools in the Comment pane to annotate the PDF and call out the changes you are requesting. If you opt to annotate the file with software other than Adobe Reader then please also highlight the appropriate place in the PDF file.

PDF ANNOTATIONS	
Adobe Reader version 9	Adobe Reader version X and XI
<p>When you open the PDF file using Adobe Reader, the Commenting tool bar should be displayed automatically; if not, click on 'Tools', select 'Comment & Markup', then click on 'Show Comment & Markup tool bar' (or 'Show Commenting bar' on the Mac). If these options are not available in your Adobe Reader menus then it is possible that your Adobe Acrobat version is lower than 9 or the PDF has not been prepared properly.</p>  <p>(Mac)</p> <p>PDF ANNOTATIONS (Adobe Reader version 9)</p> <p>The default for the Commenting tool bar is set to 'off' in version 9. To change this setting select 'Edit Preferences', then 'Documents' (at left under 'Categories'), then select the option 'Never' for 'PDF/A View Mode'.</p>  <p>(Changing the default setting, Adobe version 9)</p>	<p>To make annotations in the PDF file, open the PDF file using Adobe Reader XI, click on 'Comment'.</p> <p>If this option is not available in your Adobe Reader menus then it is possible that your Adobe Acrobat version is lower than XI or the PDF has not been prepared properly.</p>  <p>This opens a task pane and, below that, a list of all Comments in the text. These comments initially show all the changes made by our copyeditor to your file.</p> 

HOW TO...

HOW TO...		
Action	Adobe Reader version 9	Adobe Reader version X and XI
Insert text	<p>Click the 'Text Edits' button  on the Commenting tool bar. Click to set the cursor location in the text and simply start typing. The text will appear in a commenting box. You may also cut-and-paste text from another file into the commenting box. Close the box by clicking on 'x' in the top right-hand corner.</p>	<p>Click the 'Insert Text' icon  on the Comment tool bar. Click to set the cursor location in the text and simply start typing. The text will appear in a commenting box. You may also cut-and-paste text from another file into the commenting box. Close the box by clicking on 'x'  in the top right-hand corner.</p>
Replace text	<p>Click the 'Text Edits' button  on the Commenting tool bar. To highlight the text to be replaced, click and drag the cursor over the text. Then simply type in the replacement text. The replacement text will appear in a commenting box. You may also cut-and-paste text from another file into this box. To replace formatted text (an equation for example) please Attach a file (see below).</p>	<p>Click the 'Replace (Ins)' icon  on the Comment tool bar. To highlight the text to be replaced, click and drag the cursor over the text. Then simply type in the replacement text. The replacement text will appear in a commenting box. You may also cut-and-paste text from another file into this box. To replace formatted text (an equation for example) please Attach a file (see below).</p>
Remove text	<p>Click the 'Text Edits' button  on the Commenting tool bar. Click and drag over the text to be deleted. Then press the delete button on your keyboard. The text to be deleted will then be struck through.</p>	<p>Click the 'Strikethrough (Del)' icon  on the Comment tool bar. Click and drag over the text to be deleted. Then press the delete button on your keyboard. The text to be deleted will then be struck through.</p>
Highlight text/ make a comment	<p>Click on the 'Highlight' button  on the Commenting tool bar. Click and drag over the text. To make a comment, double click on the highlighted text and simply start typing.</p>	<p>Click on the 'Highlight Text' icon  on the Comment tool bar. Click and drag over the text. To make a comment, double click on the highlighted text and simply start typing.</p>
Attach a file	<p>Click on the 'Attach a File' button  on the Commenting tool bar. Click on the figure, table or formatted text to be replaced. A window will automatically open allowing you to attach the file. To make a comment, go to 'General' in the 'Properties' window, and then 'Description'. A graphic will appear in the PDF file indicating the insertion of a file.</p>	<p>Click on the 'Attach File' icon  on the Comment tool bar. Click on the figure, table or formatted text to be replaced. A window will automatically open allowing you to attach the file. A graphic will appear indicating the insertion of a file.</p>
Leave a note/ comment	<p>Click on the 'Note Tool' button  on the Commenting tool bar. Click to set the location of the note on the document and simply start typing. <u>Do not use this feature to make text edits.</u></p>	<p>Click on the 'Add Sticky Note' icon  on the Comment tool bar. Click to set the location of the note on the document and simply start typing. <u>Do not use this feature to make text edits.</u></p>

HOW TO...		
Action	Adobe Reader version 9	Adobe Reader version X and XI
Review	To review your changes, click on the 'Show' button  on the Commenting tool bar. Choose 'Show Comments List'. Navigate by clicking on a correction in the list. Alternatively, double click on any mark-up to open the commenting box.	Your changes will appear automatically in a list below the Comment tool bar. Navigate by clicking on a correction in the list. Alternatively, double click on any mark-up to open the commenting box.
Undo/delete change	To undo any changes made, use the right click button on your mouse (for PCs, Ctrl-Click for the Mac). Alternatively click on 'Edit' in the main Adobe menu and then 'Undo'. You can also delete edits using the right click (Ctrl-click on the Mac) and selecting 'Delete'.	To undo any changes made, use the right click button on your mouse (for PCs, Ctrl-Click for the Mac). Alternatively click on 'Edit' in the main Adobe menu and then 'Undo'. You can also delete edits using the right click (Ctrl-click on the Mac) and selecting 'Delete'.


SEND YOUR ANNOTATED PDF FILE BACK TO ELSEVIER

Save the annotations to your file and return as instructed by Elsevier. Before returning, please ensure you have answered any questions raised on the Query Form and that you have inserted all corrections: later inclusion of any subsequent corrections cannot be guaranteed.

FURTHER POINTS

- Any (grey) halftones (photographs, micrographs, etc.) are best viewed on screen, for which they are optimized, and your local printer may not be able to output the greys correctly.
- If the PDF files contain colour images, and if you do have a local colour printer available, then it will be likely that you will not be able to correctly reproduce the colours on it, as local variations can occur.
- If you print the PDF file attached, and notice some 'non-standard' output, please check if the problem is also present on screen. If the correct printer driver for your printer is not installed on your PC, the printed output will be distorted.

AUTHOR QUERY FORM

 ELSEVIER	Journal: YMGE Article Number: 11063	Please e-mail your responses and any corrections to: E-mail: j.s.porter@elsevier.com
--	--	--

Dear Author,

Please check your proof carefully and mark all corrections at the appropriate place in the proof (e.g., by using on-screen annotation in the PDF file) or compile them in a separate list. **It is crucial that you NOT make direct edits to the PDF using the editing tools as doing so could lead us to overlook your desired changes.** Note: if you opt to annotate the file with software other than Adobe Reader then please also highlight the appropriate place in the PDF file. To ensure fast publication of your paper please return your corrections within 48 hours.

For correction or revision of any artwork, please consult <http://www.elsevier.com/artworkinstructions>.

Any queries or remarks that have arisen during the processing of your manuscript are listed below and highlighted by flags in the proof.

Location in article	Query / Remark: Click on the Q link to find the query's location in text Please insert your reply or correction at the corresponding line in the proof
Q1	If there are any drug dosages in your article, please verify them and indicate that you have done so by initialing this query
Q2	Please check spelling of names carefully. Although every effort is made to ensure accuracy, it is ultimately your responsibility to proof these pages carefully, paying particular attention to spelling of authors' names.
Q3	Ref. 8—Please provide complete publication information. Please confirm that given names and surnames have been identified correctly and are presented in the desired order and please carefully verify the spelling of all authors' names.
	<div style="border: 1px solid black; padding: 10px;"> <p style="color: red;">Please check this box or indicate your approval if you have no corrections to make to the PDF file</p> <div style="display: inline-block; border: 1px solid black; width: 40px; height: 40px; margin-left: 20px;"></div> </div>

Thank you for your assistance.

The impact of chromoendoscopy for surveillance of the duodenum in patients with MUTYH-associated polyposis and familial adenomatous polyposis

Joanna J. Hurley, MD,^{1,2} Laura E. Thomas, PhD,¹ Sarah-Jane Walton, PhD,³ Siwan Thomas-Gibson, MD,³ Adam Haycock, MD,³ Noriko Suzuki, MD,³ Matthew Mort, PhD,¹ Geraint Williams, PhD,⁴ Meleri Morgan, MD,⁴ Susan K. Clark, MD,^{3,5} Julian R. Sampson, DM,¹ Sunil Dolwani, MD^{1,6}

Cardiff, UK; Merthyr Tydfil, UK; Harrow, UK; London, UK

Background and Aims: Duodenal polyposis and cancer have become a key issue for patients with familial adenomatous polyposis (FAP) and MUTYH-associated polyposis (MAP). Almost all patients with FAP will develop duodenal adenomas, and 5% will develop cancer. The incidence of duodenal adenomas in MAP appears to be lower than in FAP, but the limited available data suggest a comparable increase in the relative risk and lifetime risk of duodenal cancer. Current surveillance recommendations, however, are the same for FAP and MAP, using the Spigelman score (incorporating polyp number, size, dysplasia, and histology) for risk stratification and determination of surveillance intervals. Previous studies have demonstrated a benefit of enhanced detection rates of adenomas by use of chromoendoscopy both in sporadic colorectal disease and in groups at high risk of colorectal cancer. We aimed to assess the effect of chromoendoscopy on duodenal adenoma detection, to determine the impact on Spigelman stage and to compare this in individuals with known pathogenic mutations in order to determine the difference in duodenal involvement between MAP and FAP.

Methods: A prospective study examined the impact of chromoendoscopy on the assessment of the duodenum in 51 consecutive patients with MAP and FAP in 2 academic centers in the United Kingdom (University Hospital Llan-dough, Cardiff, and St Mark's Hospital, London) from 2011 to 2014.

Results: Enhanced adenoma detection of 3 times the number of adenomas after chromoendoscopy was demonstrated in both MAP ($P = .013$) and FAP ($P = .002$), but did not affect adenoma size. In both conditions, there was a significant increase in Spigelman stage after chromoendoscopy compared with endoscopy without dye spray. Spigelman scores and overall adenoma detection was significantly lower in MAP compared with FAP.

Conclusions: Chromoendoscopy improved the diagnostic yield of adenomas in MAP and FAP 3-fold, and in both MAP and FAP this resulted in a clinically significant upstaging in Spigelman score. Further studies are required to determine the impact of improved adenoma detection on the management and outcome of duodenal polyposis. (Gastrointest Endosc 2018; ■:1-8.)

INTRODUCTION

The autosomal dominant disorder familial adenomatous polyposis (FAP) and the autosomal recessive disorder

MUTYH-associated polyposis (MAP) are characterized by the development of colorectal adenomas that over time have the potential to progress to colorectal cancer. They are also defined by the development of extra-colonic

Abbreviations: APC, adenomatous polyposis coli; FAP, familial adenomatous polyposis; HGD, high-grade dysplasia; MAP, MUTYH-associated polyposis; NBI, narrow band imaging.

DISCLOSURE: All authors disclosed no financial relationships relevant to this publication.

Copyright © 2018 by the American Society for Gastrointestinal Endoscopy 0016-5107/\$36.00

<https://doi.org/10.1016/j.gie.2018.04.2347>

Received November 10, 2017. Accepted April 17, 2018.

Current affiliations: Institute of Medical Genetics, Division of Cancer and Genetics, Cardiff University School of Medicine, Cardiff (1); Prince Charles Hospital, Merthyr Tydfil (2); The Polyposis Registry, St Marks Hospital, London Northwest University Healthcare NHS Trust, Harrow (3); Department of Histopathology, University Hospital of Wales, Cardiff (4); Department of Surgery and Cancer, Imperial College, London (5); Division of Population Medicine, Cardiff University School of Medicine, Cardiff, UK (6).

Reprint requests: Dr Sunil Dolwani, 306E, Division of Population Medicine, Neuadd Meirionnydd, Heath Park, Cardiff University School of Medicine, CF14 4YS, UK.

manifestations, including duodenal adenomas and cancer, which in FAP have now become a leading cause of death as patients undergo prophylactic colectomy at an early stage in their disease. Duodenal polyposis is seen less frequently in MAP than FAP, occurring in up to 17% to 34%^{1,2} compared with 70% or more of patients with FAP,³ but the very limited available data suggest a comparable increase in relative risk and lifetime risk of duodenal cancer.

The Spigelman scoring system (Table 1) for risk stratification of duodenal polyps in FAP was developed to allow an estimation of the risk of developing duodenal carcinoma and guide surveillance intervals.⁴ The Mallorca group advocated the same upper GI surveillance program for MAP.³ In FAP, the risk of developing cancer in Spigelman stages III to IV is reported to be between 7% and 36% despite an overall cancer risk in all patients of 5%. Recent data suggest this risk may be even higher with 1 study reporting a lifetime risk of duodenal carcinoma of 18%.⁵ Accurately identifying patients at increased risk of harboring or developing duodenal cancer is the principal goal of surveillance but, because many patients with FAP develop duodenal polyps, yet most patients do not develop invasive cancer, the clinical management remains problematic. There are few published data on the natural history of duodenal adenomatosis in MAP, and only 1 retrospective study describing 92 patients undergoing upper GI surveillance.²

In the colon, there is an overall polyp miss rate of 22% using white-light endoscopy for sporadic polyps⁶ and many studies that have examined the impact of pan-chromoendoscopy on polyp detection rates. A Cochrane review of chromoendoscopy excluding patients with polyposis syndromes and inflammatory bowel disease concluded that chromoendoscopy identifies more patients with at least 1 adenoma and significantly more patients with 3 or more adenomas.⁷ The detection or miss rate of lesions within the upper GI tract has not been as widely studied, and rarely in the duodenum. Moreover, many of the factors associated with miss rates in the colon are not applicable to upper GI endoscopic examination.

The effect of chromoendoscopy on duodenal adenoma detection in MAP has not been investigated. This study aims to evaluate the use of dye spray with indigo carmine in the duodenum to improve the identification of polyps that may be overlooked during standard white-light endoscopic examination. It also aims to determine the impact of dye spray on Spigelman stage and to compare this in individuals with MAP and FAP.

METHODS

The research was approved by the South-East Wales research ethics committee in January 2010 (reference number 10-MRE09-43) and the North West London Hospitals NHS Trust (reference number RD12/078). Cases for the study were recruited prospectively. Patients with

TABLE 1. Modified Spigelman classification of duodenal polyposis in FAP

	1 point	2 points	3 points
No. of polyps	1-4	5-20	>20
Polyp size (mm)	1-4	5-10	>10
Histology	Tubular	Tubulovillous	Villous
Dysplasia	Low grade		High grade

Stage 0, 0 points; stage I, 1 to 4 points; stage II, 5 to 6 points; stage III, 7 to 8 points; stage IV, 9 to 12 points.

confirmed FAP or MAP on genetic testing were recruited from University Hospital Llandough, Cardiff, UK, the Institute of Medical Genetics, University Hospital of Wales, Cardiff, UK, and St Marks Hospital, Harrow, UK. All patients gave informed consent. There were no healthy volunteer controls recruited for the study. Between August 2011 and January 2014, 51 consecutive patients scheduled for surveillance endoscopy of the upper GI tract were invited to participate in the study. The endoscopies were performed in 2 academic centers in the UK (University Hospital Llandough, Cardiff, and St Mark's Hospital, London).

At each center, experienced endoscopists performed all endoscopies for this study (S.D., J.H., A.H., and N.S.) using high-resolution forward-viewing video endoscopes (GIF-Q260, GIF-H260, GIF XQ260; Olympus Medical Systems) and a side-viewing duodenoscope for optimal visualization of the ampulla. Procedures were performed with the patients under general anesthetic (propofol) or conscious sedation using standard doses of fentanyl and midazolam in line with British Society of Gastroenterology guidance,⁸ depending on patient preference and the presence of comorbid conditions. Antispasmodic medication (hyoscine butylbromide) was given during endoscopy at the discretion of the endoscopist.

At introduction, the forward-viewing endoscope was advanced until the duodeno-jejunal junction was reached. During withdrawal, the different parts of the duodenum (D2, D3, and duodenal bulb) were evaluated, and the number and sizes of polyps recorded on a standardized proforma before staining with indigo carmine dye (Fig. 1). Polyp size was estimated using Radial Jaw 3 biopsy forceps (Boston Scientific, Natick, Mass), with a closed diameter of 2.2 mm and an open diameter of 8 mm. The endoscopist then sprayed a 0.3% solution of indigo carmine (3 mL of indigo carmine 1% and 7 mL of water for injection) from D3 proximally to the duodenal bulb onto the duodenal mucosa, distributed in a homogeneous fashion by a spraying catheter passed through the endoscope channel. The residual dye was then suctioned away. After adequate coating of the duodenum with the dye solution, a second endoscopist unaware of the findings and polyp count from the first part of the examination, recorded the size and number of polyps seen (Fig. 2). Biopsy samples were not taken

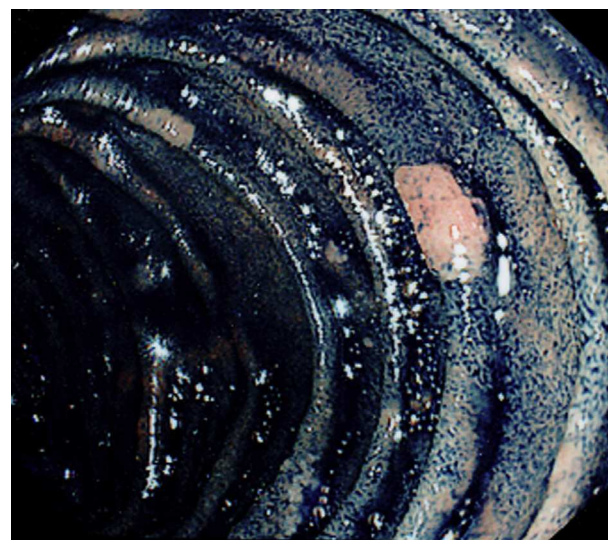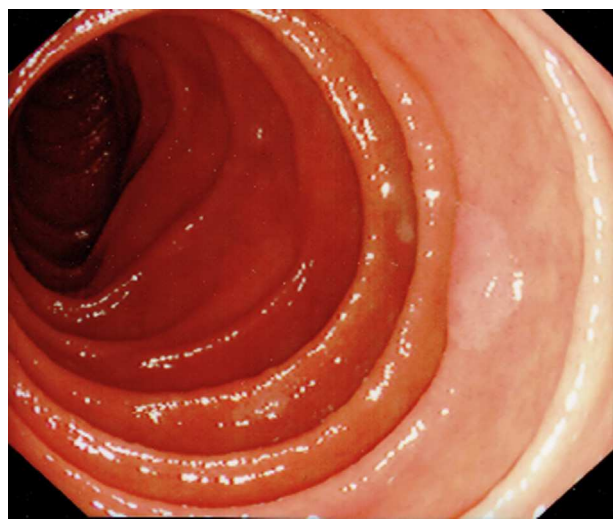


Figure 1. Duodenum of a patient with 1999 before chromoendoscopy.

Figure 2. Duodenum of the same patient with FAP after chromoendoscopy.

until after staining and counting had taken place. Samples were taken from all lesions with high-grade morphology (disrupted surface pattern, ulceration, or depressed areas within the polyp) and lesions greater than 1 cm. If the number of polyps was small, all lesions were sampled, but if there were numerous polyps, at least 3 of the largest adenomas were sampled in addition to the criteria above. To further aid accurate staging of duodenal disease, our protocol asked for examination using a side-viewing endoscope in patients where the ampulla was inadequately visualized using the forward-viewing endoscope. If it appeared adenomatous, biopsy specimens were taken. All procedures were conducted using the same structural and color enhancement settings in both centers.

For all patients, Spigelman point totals and stage before and after the application of chromoendoscopy were assessed. The following criteria were used: number of adenomas, largest size, the most advanced histology, and most advanced grade of dysplasia. All lesions sampled for histology were confirmed as adenomas. The biopsy specimens were evaluated by 2 expert gastrointestinal pathologists (M.M. and G.T.W.) who graded dysplasia according to the Vienna (low-grade/high-grade) classification⁹ and the 3-tier grading system used by Spigelman et al.⁴

Statistical analysis

Statistical analysis for the study was performed using R (version 3.0.2) software. Statistical significance for the frequency of duodenal adenomas was calculated using the Wilcoxon signed-rank test and Mann-Whitney U test, and a one-sided sign test was used to compare the Spigelman stages. A *P* value of less than .05 was considered statistically significant. The study was powered for 92% at a 5% significance level to detect a difference in the number of polyps in MAP versus FAP (1 degree of freedom using a

chi-squared test to compare the 2 conditions). Statistical data are expressed as medians.

RESULTS

Between August 2011 and January 2014, 51 patients (19 FAP and 32 MAP) underwent gastroduodenoscopies. Of the FAP patients, 8 were female and 11 were male; median age was 41 years (range, 32-69 years). There were 17 female and 15 male patients with MAP; median age 54 years (range, 25-81 years). No patient was on any pharmacological treatments for their duodenal disease or for their colonic disease. There were no adverse events relating to endoscopic examination (bleeding or perforation), and no adverse events relating to general anesthesia or sedation were observed.

Patients in the MAP group were significantly older than those with FAP ($P = .001$). There was no difference in the calculated overall Spigelman stage before or after dye spraying for any patient when comparing the traditional 3-tiered grading system with the modified (Vienna classification) Spigelman score.

Number of adenomas

In MAP patients before staining, 10 lesions were found in 32 patients (range, 0-6), and this increased significantly to 34 lesions after dye spraying (range, 0-15) (Table 2). Additional duodenal adenomas were detected in 9 patients (28%). The median number of additional adenomas detected was 2 per patient (total, 24; range, 1-9).

The median number of adenomas in the FAP cohort with white light, per patient, was 4 (total, 150; range, 0-46). After staining, the median number of adenomas detected was 14 per patient (total, 442; range, 0-100)

TABLE 2. Duodenal adenoma characteristic in patients with MAP (n = 32)

Gastroduodenoscopy findings	Pre-staining	Post-staining	P value
Median number of duodenal adenomas (total)	0 (10)	0 (34)	.01368*
Largest size (mm), median (range)	5 (2-50)	6 (2-50)	.3711
Spigelman stage, median (range)	0 (0-III)	0 (0-III)	.03125*

Despite no change in the median Spigelman scores, the Mann-Whiney and Wilcoxon tests are rank sum tests and not median tests. It is possible for groups to have different rank sums and yet have equal or nearly equal medians.

*Statistically significant difference ($P < .05$).

($P = .0002$) (Table 3). Additional adenomas after chromoendoscopy were detected in 13 patients (68% of FAP cases).

The number of duodenal adenomas observed after staining was significantly higher in FAP than MAP ($P = .0002452$; Mann-Whitney U test).

Size of adenomas

The median largest adenoma size was 5 mm compared with 6 mm after dye spray in MAP, and the size of the largest adenomas (15 mm, 15 mm, 25 mm, and 50 mm) did not change after dye spraying with indigo carmine.

In FAP, there was also no statistically significant change in the median adenoma size after staining. No statistically significant difference was observed between the post-staining size of the largest duodenal adenomas observed in MAP versus FAP ($P \approx 1$; Mann-Whitney U test). There was no significant statistical difference in the overall numbers of adenomas greater than 1 cm in patients with MAP versus FAP before or after staining ($P \approx 1$; Mann-Whitney U test).

The numbers of polyps of different sizes detected after chromoendoscopy in MAP and FAP are given in Tables 4 and 5.

Histology of adenomas

All polyps in patients with MAP were tubular adenomas with low-grade dysplasia. Three patients had moderate-grade dysplasia when assessed according to the 3-grade system used by Spigelman et al.⁴ Among the cases of FAP, there were tubular adenomas in 8 patients (42%), tubulovillous adenomas in 4 patients (21%), and villous adenoma in 1 patient (5%), all with low-grade dysplasia. Four of the patients with FAP had moderate dysplasia according to the Spigelman criteria,⁴ with no high-grade dysplasia (HGD) detected.

Endoscopic technique

Use of the side-viewing endoscope did not detect any additional ampullary adenomas compared with the

TABLE 3. Duodenal adenoma characteristics in patients with FAP (n = 19)

Gastroduodenoscopy findings	Pre-staining	Post-staining	P value
Number of duodenal adenomas, median (total)	4 (150)	14 (442)	.002516*
Largest size (mm), median (range)	6 (2-23)	6 (2-30)	.1814
Spigelman stage, median (range)	II (0-IV)	II (0-IV)	.03125*

*Statistically significant difference ($P < .05$).

forward-viewing endoscope, and only 1 patient had an ampullary adenoma detected in this study. One patient was observed to have 4 further polyps detected by side-viewing endoscopy after dye spraying and counting. Twenty-three patients (45%) of the total cohort of 51 required side-viewing endoscopy to ensure clear ampullary visualization.

Spigelman staging

Before dye spraying, the Spigelman classification was stage 0 in 27 patients (84%), stage I in 2 patients (6.25%), stage II in 2 patients (6.25%), and stage III in 1 patient (3.5%) with MAP (Table 6). Staining resulted in an increased Spigelman point total in 9/32 individuals (28%), with a corresponding upgrade in Spigelman stage in 6 patients (18%) (from 0 to I, $n = 1$; from 0 to II, $n = 3$; from I to II, $n = 2$; $P < .05$). Among the patients with FAP, staining resulted in an increased Spigelman point total in 13 of 19 individuals (68%), with a corresponding upgrade in Spigelman stage in 5 patients (26%) (from 0 to I, $n = 1$; from I to II, $n = 1$; from I to III, $n = 2$; from III to IV, $n = 1$; $P < .05$).

The post-staining Spigelman stage is significantly higher in FAP versus MAP ($P = .0009646$; Mann-Whitney U test). The change in Spigelman grade reflected the increased number of adenomas detected.

Mutation data

The mutation analysis of the 32 patients with MAP and the total number of duodenal adenomas detected are presented in Table 7.

DISCUSSION

This study is the first to assess the impact of chromoendoscopy in the evaluation of duodenal adenomas in patients with MAP, a group in which upper GI disease has not been extensively studied, and compares this to the findings in patients with FAP. Potential applications of chromoendoscopy within the upper GI tract in FAP appear promising; the diagnostic yield of standard surveillance

TABLE 4. Adenoma numbers by size pre-and post-staining in MAP

Case	No. of polyps					
	1-4 mm		5-10 mm		>10 mm	
	Pre-staining	Post-staining	Pre-staining	Post-staining	Pre-staining	Post-staining
1-3, 5-11, 14, 16, 17, 22, 24-27, 29-32	0	0	0	0	0	0
4	0	1	0	0	0	0
12	0	6	2	6	2	2
13	0	0	0	1	0	0
15	1	2	1	1	0	0
18	0	0	1	1	0	0
19	0	0	1	2	0	0
20	0	1	0	1	1	1
21	0	0	0	1	1	1
23	0	2	0	1	0	0
28	0	3	0	1	0	0

TABLE 5. Number of adenoma by size pre-and post-staining in FAP

Case	No. of polyps					
	1-4 mm		5-10 mm		>10 mm	
	Pre-staining	Post-staining	Pre-staining	Post-staining	Pre-staining	Post-staining
33-34, 41-42, 48-49	0	0	0	0	0	0
35	3	10	4	7	0	0
36	14	34	5	22	5	5
37	0	1	0	0	0	0
38	8	19	10	18	0	0
39	1	13	5	8	0	0
40	1	3	2	3	0	0
43	29	81	14	23	3	3
44	8	53	4	21	2	2
45	0	6	0	2	0	0
46	5	6	1	25	4	4
47	4	12	0	4	0	0
50	2	4	8	10	0	0
51	4	11	3	15	0	0

upper GI endoscopy was demonstrated to be improved by dye spraying alone in a small study of 10 patients with FAP undergoing upper GI endoscopic surveillance.¹⁰ A more recent study of 43 patients also demonstrated that chromoendoscopy increased the detection of duodenal adenomas in FAP but did not lead to a considerable change in the Spigelman stage.¹¹

This study demonstrates that there is a significant increase in the numbers of duodenal adenomas identified after indigo carmine dye spraying in cases of both MAP and FAP, and that this resulted in a significant increase in the

Spigelman stage in both conditions. This study identified duodenal adenomas in 28% of patients with MAP, similar to the series recently reported by Walton et al² who identified duodenal adenomas in 34% of patients with MAP, and higher than the 17% observed in a previous multicenter European study.¹

Two previous studies have assessed adenoma number while investigating the role of chromoendoscopy in the duodenum in FAP. Picasso et al¹⁰ studied 10 patients undergoing upper GI surveillance and found a statistically significant increase in the number of duodenal polyps

TABLE 6. Distribution of Spigelman stages in patients with FAP and MAP before and after staining, compared with results reported in previous case series of patients with FAP

Spigelman stage	Present series MAP (n = 32), n (%)		Present series FAP (n = 19), n (%)		Previous case series ¹¹ (n = 43 FAP), n (%)	
	Before staining	After staining	Before staining	After staining	Before staining	After staining
0	27 (84)	23 (72)	7 (37)	6 (32)	3 (7)	2 (4)
I	2 (6.25)	1 (3)	2 (10)	1 (5)	2 (4)	2 (4)
II	2 (6.25)	7 (22)	4 (21)	4 (21)	11 (26)	10 (23)
III	1 (3.5)	1 (3)	3 (16)	4 (21)	14 (33)	15 (36)
IV	0	0	3 (16)	4 (21)	13 (30)	14 (33)

after chromoendoscopy ($P = .03$), revealing additional polyps in 8 of the 10 patients. Unlike our study, the overall change in Spigelman stage was not assessed. Dekker et al¹¹ studied 43 patients with FAP and showed that significantly more duodenal adenomas were detected after the application of indigo carmine, but this did not result in a considerable change in Spigelman stage or result in any major additional clinical consequences. Of the 43 patients, only 26 had an APC mutation that had previously been identified; the other 17 patients all had undergone colectomy because of >100 histologically confirmed colorectal adenomas but without confirmation of pathogenic mutations. In contrast, our cohort of patients comprises a specific subgroup with known mutations. In addition, the endoscopist in Dekker et al.'s study was not blinded to the number of adenomas before staining, which may have biased the results. Although our current study was designed to blind the second counting endoscopist, there remains the possibility of a systematic bias due to counting differences between the 2 endoscopists. Both previous studies of dye spray duodenoscopy are in agreement with our findings in FAP, but the impact on adenoma detection in MAP has never been studied and is a novel finding.

The small number of patients with MAP reported to have developed duodenal cancer appear to have done so on a background of minimal duodenal polyps,¹ in contrast to those with FAP, and it is not necessarily that the total polyp number is as important as other factors in the assessment of duodenal cancer risk in patients with MAP. Recent molecular genetic analysis revealed a greater burden of somatic mutations in MAP than in FAP adenomas, suggesting the MAP-associated DNA repair defect may drive a more rapid progression of adenoma to cancer.¹² Although none of the studies to date have established the clinical interpretation of multiplicity of duodenal adenomas in MAP, the improved adenoma detection rate seen in MAP after chromoendoscopy in this study has the potential to be clinically meaningful, because it is likely to lead to more appropriate surveillance intervals for some patients.

Generally, in studies of the outcomes of surgical intervention in FAP, it is the patient's Spigelman stage that has been reported rather than the sizes of lesions harboring cancer.^{5,13,14,15} Lopez-Ceron et al¹⁶ found that when using narrow band imaging (NBI) for detection of duodenal adenomas, the only trait that was significantly associated with advanced histology was an estimated polyp size of greater than 1 cm, with a 3-fold increased risk. Although high Spigelman stages do not necessarily imply advanced histologic lesions, Saurin et al¹³ reported that an original Spigelman score equal to or greater than 7 or 8 was predictive of HGD development. The use of chromoendoscopy in the colon to highlight high-risk features for biopsy, such as an advanced Kudo pit pattern, which may be overlooked by white-light endoscopy, has been described in the literature, and use of image enhancement techniques (digital or chromoendoscopic) can improve diagnostic accuracy in lesion assessment.¹⁷ In the duodenum, this may also be of direct benefit to identify advanced surface characteristics and enable targeted biopsy.

This study has shown no significant effect of chromoendoscopy on the sizing of adenomas in either MAP or FAP. Dekker et al¹¹ reported that the largest adenomas detected at chromoendoscopy appeared significantly larger than before staining, possibly due to better visualization of the adenoma borders. In contrast, Picasso et al¹⁰ reported that polyps appeared smaller after dye spraying ($P = .03$), which was also explained by more precise demarcation than normal. Although some lesions may look larger or smaller after dye spray, the detection of additional smaller lesions would of course result in a smaller median size of polyps detected. Our study suggests that, like NBI,¹⁶ chromoendoscopy does not significantly affect the apparent size of adenomas in the FAP duodenum.

Dekker et al¹¹ attributed the minor change in Spigelman score in their study to the use of high-resolution endoscopy. They concluded that considerably improved endoscopic visualization of duodenal adenomatosis with high-resolution endoscopy leaves little room for further improvement of clinical consequence. However, the

TABLE 7. MAP mutation analysis data and number of duodenal adenomas detected

Case	Mutation 1	Mutation 2	Total number of duodenal polyps detected
1	Y104X	Y104X	0
2	G396D	G396D	0
3	Y179C	V130EfsX98	0
3	Y179C	Y179C	1
5	E480X	E480X	0
6	Y179C	G396D	0
7	Y179C	G396D	0
8	Y179C	Y179C	0
9	Y179C	G396D	0
10	Y104X	Y104X	0
11	Y104X	Y104X	0
12	Y179C	Y179C	15
13	Y104X	Y104X	1
14	Y104X	Y104X	0
15	Y179C	G396D	1
16	E466X	E466X	0
17	E466X	E466X	3
18	Gln 414 + Gln 414 + Tyr 104	1240 C>T + 312 C>A	0
19	E466X	E466X	0
20	E466X	E466X	1
21	E480X	E466X	3
22	E480X	E466X	2
23	E480X	E466X	0
24	E466X	E466X	3
25	E480X	E466X	0
26	E480X	E466X	0
27	E466X	E466X	0
28	Y179C	Y179C	4
29	Y179C	Y179C	0
30	E480X	E466X	0
31	E480X	E466X	0
32	Y179C	R244X	0

endoscopist was not blinded to the number of adenomas before staining. A previous study has suggested that in patients who have duodenal disease progression, both time lapse and technical improvements were determinant factors.¹⁸ In a mixed-model analysis, time lapse, change to high-resolution technology, and dysplasia ranking contributed consistently to an increased Spigelman score and stage. This suggests visibility and histology may result in an overestimation of the clinical significance of duodenal polyposis by using the Spigelman system. However, other studies appear to demonstrate a lack of correlation

between the findings at endoscopy and pathology results from biopsy specimens, and between progressive structural changes within the polyps and pathology findings.¹⁹ This led the authors to argue that the overall aim of identifying patients who are at high risk of developing duodenal and ampullary cancer remains problematic. Currently, there is no comprehensive picture of the risk of duodenal adenomas and cancer in patients with MAP, and the risks of duodenal disease remains uncertain. Further research is required to prospectively validate the Spigelman classification in the risk stratification of duodenal polyposis, because its suitability for MAP has not been established.

Lopez-Ceron et al¹⁶ are the only group to have evaluated the effect of NBI (after examination with high-resolution endoscopy) on the detection rates of duodenal adenomas in patients with FAP. In contrast to this current study, they found that in their study group of 37 patients, there was no clinically relevant upgrade in the Spigelman classification using NBI. They also concluded that there was no improvement in the detection of gastric polyps using NBI. More duodenal adenomas were detected in 16 examinations (35.6%), but Spigelman stage increased in only 2 patients (2.2%), which was not statistically significant. The current study therefore supports the use of chromoendoscopy over NBI in the improvement of adenoma detection in duodenal polyposis, but larger prospective studies are needed to confirm this.

The patients with MAP in this study were significantly older than the patients with FAP. In patients with FAP, time since diagnosis, age, and Spigelman stage at initial endoscopy have been found to be determining features of the severity of duodenal polyposis.^{3,13,20,21} These variables may not apply for MAP. Our study suggests that the effect of increasing age on the number of polyps is not the same for MAP as it is for FAP. The natural history of duodenal polyposis in MAP is a topic that requires further study.

A limitation of this study is the inability to determine the additional value of chromoendoscopy in the assessment of ampullary adenomas; because examination of this area with the side-viewing endoscope was done after dye spraying had taken place (current recommendations suggest use of a side-viewing duodenoscopy as standard). We found that almost half of the patients required further side-viewing endoscopy to satisfactorily visualize the ampulla, suggesting this should continue to be included in protocols for duodenal surveillance. In addition, our study was not designed to systematically assess the utility of side-viewing endoscopy itself on the number of polyps in the peri-ampullary region. A previously reported case series found ampullary adenomas in 66% of patients with FAP when using a side-viewing endoscope,²² however our study did not detect many ampullary adenomas (only 2 patients had ampullary adenomas), which may have caused bias because most malignancies occur in the periampullary region. No lesions with HGD were

781 detected, and our series may not be representative of the
 782 FAP and MAP population although it involves 2 large UK
 783 centers with relatively high-volume surveillance caseloads
 784 for polyposis. In their prospective five-nation study of the
 785 long-term natural history duodenal adenomas in FAP, Bu-
 786 low et al²¹ reported that 12% of adenomas were
 787 diagnosed only histologically, where no visible polyps
 788 were seen. The current study did not incorporate taking
 789 routine biopsy specimens of the background duodenal
 790 mucosa to exclude dysplasia and relied on visualization
 791 of precisely demarcated adenomatous tissue as
 792 morphologic polyps. Picasso et al¹⁰ did take random
 793 biopsy specimens of mucosal folds in the second and
 794 upper third part of the duodenum, including the papilla,
 795 but found no additional adenomatous tissue. Dekker
 796 et al¹¹ did not include taking random background biopsy
 797 specimens in their protocol.

799 CONCLUSIONS

800 This study demonstrates that chromoendoscopy of the
 801 duodenum enhances adenoma detection in both MAP
 802 and FAP, and that use of a side-viewing endoscope is
 803 essential to ensure that the ampulla is adequately visual-
 804 ized. In both conditions, there was a significant increase
 805 in Spigelman stage after chromoendoscopy and therefore
 806 of clinical consequence to the patient in terms of follow-
 807 up according to current management guidelines. The in-
 808 crease in Spigelman stage was due to increased detection
 809 of numbers of polyps rather than by enlarged polyps or
 810 high-grade adenomas. Because screen-detected duodenal
 811 cancers have been shown to have a much better prognosis
 812 than symptomatic cancers in FAP (overall survival of 8 years
 813 after a screen-detected cancer versus 0.8 years⁵), there is a
 814 strong argument for regular endoscopic surveillance.
 815 However, there are shortcomings in applying the same
 816 surveillance program to MAP as for FAP because of a
 817 paucity of knowledge of the risk of malignant
 818 progression in MAP duodenal adenomas. Further studies
 819 are needed to focus on this question.

823 REFERENCES

- 825 1. Vogt S, Jones N, Christian D, et al. Expanded extracolonic tumour
 826 spectrum in MUTYH-associated polyposis. *Gastroenterology*
 827 2009;137:1976-85.
- 828 2. Walton SJ, Kallenberg FG, Clark SK, et al. Frequency and features of
 829 duodenal adenomas in patients with MUTYH-associated polyposis.
 830 *Clin Gastroenterol Hepatol* 2016;14:986-9.
- 831 3. Vasen HFA, Moslein G, Alonso A, et al. Guidelines for the clinical man-
 832 agement of familial adenomatous polyposis (FAP). *Gut* 2008;57:704-13.
- 833 4. Spigelman AD, Williams CB, Talbot IC, et al. Upper gastrointestinal
 834 cancer in patients with familial adenomatous polyposis. *Lancet* 1989
 835 ii:783-5.
- 836 5. Bülow S, Christensen IJ, Bjork J, et al. Duodenal surveillance improves
 the prognosis after duodenal cancer in familial adenomatous polyposis.
Colorectal Dis 2011;14:947-52.
6. Van Rijn JC, Reitsma JB, Stoker J, et al. Polyp miss rate determined by
 tandem colonoscopy: a systematic review. *Am J Gastroenterol*
 2006;115:343-50.
7. Brown SR, Baraza W. Chromoendoscopy versus conventional endos-
 copy for the detection of polyps in the colon and rectum. *Cochrane*
Database Syst Rev 2007;4:CD006439.
8. British Society of Gastroenterology. Safety and sedation during endo-
 scopic procedures. *British Society of Gastroenterology*; 2006.
9. Schlemper RJ, Riddell RH, Kato Y, et al. The Vienna classification of
 gastrointestinal epithelial neoplasia. *Gut* 2000;47:251-5.
10. Picasso M, Filiberti R, Bianchi S, et al. The role of chromoendoscopy in
 the surveillance of the duodenum of patients with familial adenoma-
 tous polyposis. *Dig Dis Sci* 2007;52:1906-9.
11. Dekker E, Bopari KS, Poley JW, et al. High resolution endoscopy and the
 additional value of chromoendoscopy in the evaluation of duodenal
 adenomatosis in patients with familial adenomatous polyposis. *Endos-
 copy* 2009;41:666-9.
12. Thomas LE, Hurley JJ, Meuser E, et al. Burden and profile of somatic
 mutation in duodenal adenomas from patients with familial adenoma-
 tous- and MUTYH-associated polyposis. *Clin Cancer Res* 2017;23:
 6721-32.
13. Saurin J-C, Gutknecht C, Napoleon B, et al. Surveillance of duodenal ad-
 enomas in familial adenomatous polyposis reveals high cumulative
 risk of advanced disease. *J Clin Oncol* 2004;22:493-8.
14. Van Heumen BWH, Nieuwenhuis MH, van Goor H, et al. Surgical man-
 agement for advanced duodenal adenomatosis and duodenal cancer
 in Dutch patients with familial adenomatous polyposis: a nationwide
 retrospective cohort study. *Surgery* 2012;151:681-90.
15. Serrano PE, Grant RC, Berk TC, et al. Progression and management of
 duodenal neoplasia in familial adenomatous polyposis. *Ann Surg* 2014:
 1-7.
16. Lopez-Ceron M, van den Brock F, Mathus-Vliegen E, et al. The role of
 high resolution endoscopy and narrow band imaging in the evaluation
 of upper GI neoplasia in familial adenomatous polyposis. *Gastrointest*
Endosc 2013;77:542-50.
17. Rutter MD, Chatree A, Barbour JA, et al. British Society of Gastroenter-
 ology/Association of Coloproctologists of Great Britain and Ireland
 guidelines for the management of large non-pedunculated colorectal
 polyps. *Gut* 2015;64:1847-73.
18. Mathus-Vliegen EMH, Bopari KS, Dekker E, et al. Progression of
 duodenal adenomatosis in familial adenomatous polyposis: due to
 ageing of subjects and advances in technology. *Familial Cancer*
 2011;14:491-9.
19. Moozar K, Malinski L, Berk T, et al. Slow progression of periampullary
 neoplasia in familial adenomatous polyposis. *J Gastrointest Surg*
 2002;6:831-7.
20. Saurin J-C, Ligneau B, Ponchon T, et al. The influence of mutation site
 on the severity of duodenal polyposis in patients with familial adeno-
 matous polyposis. *Gastrointest Endosc* 2002;55:342-7.
21. Bülow S, Bjork J, Christensen IJ, et al. Duodenal adenomatosis in
 familial adenomatous polyposis. *Gut* 2004;53:381-6.
22. Burke CA, Beck GJ, Church JM, et al. The natural history of untreated
 duodenal and ampullary adenomas in patients with familial adeno-
 matous polyposis followed in an endoscopic surveillance program.
Gastrointest Endosc 1999;49:358-64.