

Case Report

A case report on development of CNS primitive neuroectodermal tumour from astrocytoma

Sunnia Gupta*, Narendra Rathore

Department of Radiotherapy, RNT Medical College Udaipur, Rajasthan, India

Received: 6 August 2014

Accepted: 5 September 2014

***Correspondence:**

Dr. Sunnia Gupta,

E-mail: guptasunnia@yahoo.in

Copyright: © the author(s), publisher and licensee Medip Academy. This is an open-access article distributed under the terms of the Creative Commons Attribution Non-Commercial License, which permits unrestricted non-commercial use, distribution, and reproduction in any medium, provided the original work is properly cited.

ABSTRACT

CNS PNET are infrequent in children and very rare in adults. Even rarer is the development of PNET from low grade astrocytoma. We hereby report a case of PNET arising from astrocytoma. Some similar cases have been reported in the past in which radiation was considered to be the etiological factor in the development of PNET from glial neoplasms but in this case the duration of conversion does not go in favour of radiation as the cause.

Keywords: PNET, Astrocytoma, k-Ras, Radiation therapy

INTRODUCTION

CNS PNET are infrequent in children and very rare in adults with an overall incidence of 0.26 per 100000 person years reported by Central Brain Tumour Registry of the United States (CBTRUS).

Overall it represents only 1.8% of all brain tumours. We hereby report a case of PNET arising from astrocytoma.

CASE REPORT

A 22 year old female unmarried patient presented with periodic attacks of black outs in 2010. Her CT scan revealed a brain SOL. CT scan (Figure 1) report showed a hypodense lesion non-enhancing about 8.6x6.7x5.8 cm in left temporo-parietal lobe.

She was operated and histopathology report from three different academic pathology laboratories showed astrocytoma grade I, astrocytoma grade II, and diffuse fibrillary astrocytoma grade II.

Postoperatively, the patient received cranial irradiation in 31fr from 17/1/2011 to 25/2/2011.

She remained asymptomatic for two years after which she developed pain and swelling at the operated site. In March 2013, CT scan revealed a recurrent non enhancing hypodense mass 5.6x4.6 cm in left fronto-parietal lobe causing midline shift (Figure 2). Patient was operated for second time. Pathology report showed diffuse fibrillary astrocytoma grade II.

Patient's symptoms progressed post-operatively and seven months later, MRI brain revealed a large 7.0x7.0x6.6 cm non enhancing mass with evidence of solid and cystic component in the left temporal lobe, peri-insular and parietal region (Figure 3) for which she was operated the third time in October, 2013. In post-op MRI, there was a residual enhancing intra axial mass 5.7x7.2x5.2 cm in left temporal lobe with midline shift which was isointense on T1W and hyperintense on T2W& FLAIR sequence. Histopathology report showed glioblastoma with PNET.

IHC was done and it was focally positive for neuron specific enolase and GFAP, negative for synaptophysin, and 60% positive for Ki67.

Review of all previous biopsy blocks was done.

16/7/2010 - Diffuse astrocytoma grade II

16/3/2013 - Glioblastoma grade IV

30/10/2013 - Glioblastoma with Primitive Neuroectodermal tumour (PNET)

Treatment in the form of cisplatin and etoposide based chemotherapy was started. After two chemotherapy cycles patients general condition deteriorated. A mass was seen protruding from the operative site. So palliative radiotherapy in order to relieve symptoms was started but the patient succumbed to death while on radiotherapy in Feb, 2014.

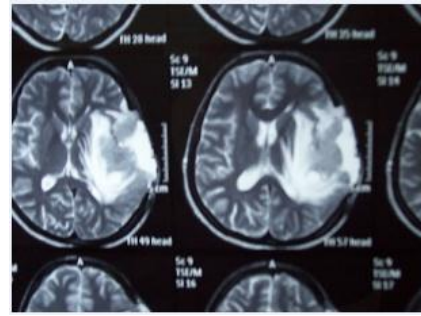


Figure 3: MRI brain revealed a large 7.0x7.0x6.6 cm non enhancing mass with evidence of solid and cystic component in the left temporal lobe, peri-insular and parietal region.

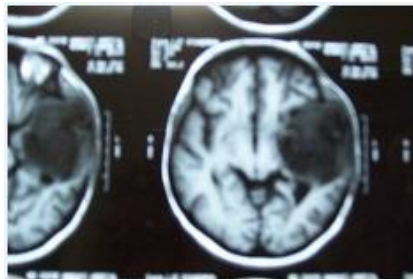


Figure 1: CT scan report showed a hypodense lesion non-enhancing about 8.6x6.7x5.8 cm in left temporo-parietal lobe.

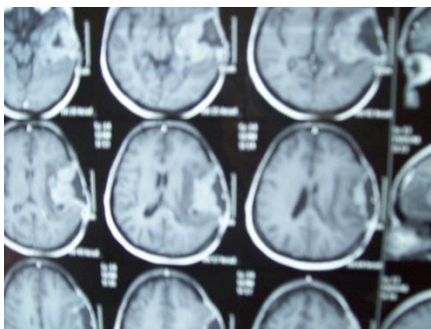


Figure 2: CT scan revealed a recurrent non enhancing hypodense mass 5.6x4.6 cm in left fronto-parietal lobe causing midline shift.

DISCUSSION

The development of brain tumours in previously irradiated sites is a rare complication of cranial irradiation.^{1,2} Other possible risk factors for these secondary CNS tumours include younger age at irradiation, genetic predisposition to cancer, and genetic polymorphisms in certain metabolizing enzymes, such as thiopurine s-methyl-transferase.² The most commonly reported histologic types of these tumours are the high-grade gliomas, including glioblastomas and malignant astrocytomas.¹ Nevertheless, cases of meningiomas, schwannomas, sarcomas, and PNETs arising in the CNS after cranial irradiation have also been described.¹⁻⁵ Secondary PNETs have been reported in 11 patients at a mean of 8.5 years following a relatively low-dose prophylactic craniospinal irradiation (18-24 Gy) and intrathecal methotrexate for leukemia and lymphoma.³ In addition, a supratentorial secondary PNET was reported to occur in a patient with unilateral sporadic retinoblastoma 5 years after surgery, low-dose cranial irradiation (27.6 Gy), and intrathecal methotrexate.⁴ In these cases, the relative contribution of low-dose irradiation versus intrathecal methotrexate to the development of PNET is not clear.

As compared to other cases reported in the past (Table1), in our case patient developed PNET within 2 years of cranial irradiation.

Table 1: A review of previous case reports.

Nr	Sex/age	Location	Primary tumor	Therapy (Gy/fractions)	Latency to PNET	Survival
1	M 4	R occipital	Oligodendroglioma grade II	44/20	29 months	36 months
2	F 6	Cerebellar	Pilocytic astrocytoma grade I	5000 c/25	11 years	11 months
3	M 9	Cerebellar	Malignant ependymoma	3500 c/18 2000 c/10 boost	16 years	18 months
4	M 37	Temporal	Astrocytoma grade II	5000 c/25	5 years	6 months
5	M 17	IV ventricle	Astrocytoma grade II	3400 c/17 1600 c/8 boost 2500 c/45	18 years	12 months
6	M 30	L parietal	Astrocytoma grade II	54/30	10 years	9 months

PNETs describe a group of histologically similar neoplasms composed of embryonal small cells that may be undifferentiated or may have varying degrees of neuronal, glial, or mesenchymal differentiation. PNETs of the CNS include medulloblastomas, neuroblastomas, pineoblastomas, and ependymoblastomas.

The exact mechanism of the development of PNETs after cranial irradiation is unknown, although it has been speculated to involve the persistence of a population of undifferentiated neuroepithelial cells in the CNS, as well as genetic mutations involving oncogenes such as K-ras.^{3,5}

As it seems unlikely that cranial irradiation to be the cause of development of PNET in this case further research is required in this field to find the cause and PNET arising from astrocytoma may be considered a possibility.

Funding: No funding sources

Conflict of interest: None declared

Ethical approval: Not required

REFERENCES

1. Salvati M, Frati A, Russo N. Radiation-induced gliomas: report of 10 cases and review of the literature. *Surg Neurol.* 2003;60:60-7.
2. Robison LL, Bhatia S. Late-effects among survivors of leukaemia and lymphoma during childhood and adolescence. *Br J Haematol.* 2003;122:345-59.
3. Brustle O, Ohgaki H, Schmitt HP. Primitive neuroectodermal tumors after prophylactic central nervous system irradiation in children. Association with an activated K-ras gene. *Cancer.* 1992;69:2385-92.
4. Dorfmueller G, Wurtz FG, Kleinert R, Lanner G. Cerebral primitive neuro-ectodermal tumour following treatment of a unilateral retinoblastoma. *Acta Neurochir (Wien).* 1997;139:749-55.
5. Hader WJ, Drovini-Zis K, Maguire JA. Primitive neuroectodermal tumors in the central nervous system following cranial irradiation: a report of four cases. *Cancer.* 2003;97:1072-6.

DOI: 10.5455/2320-6012.ijrms20141194

Cite this article as: Gupta S, Rathore N. A case report on development of CNS primitive neuroectodermal tumour from astrocytoma. *Int J Res Med Sci* 2014;2:1726-8.