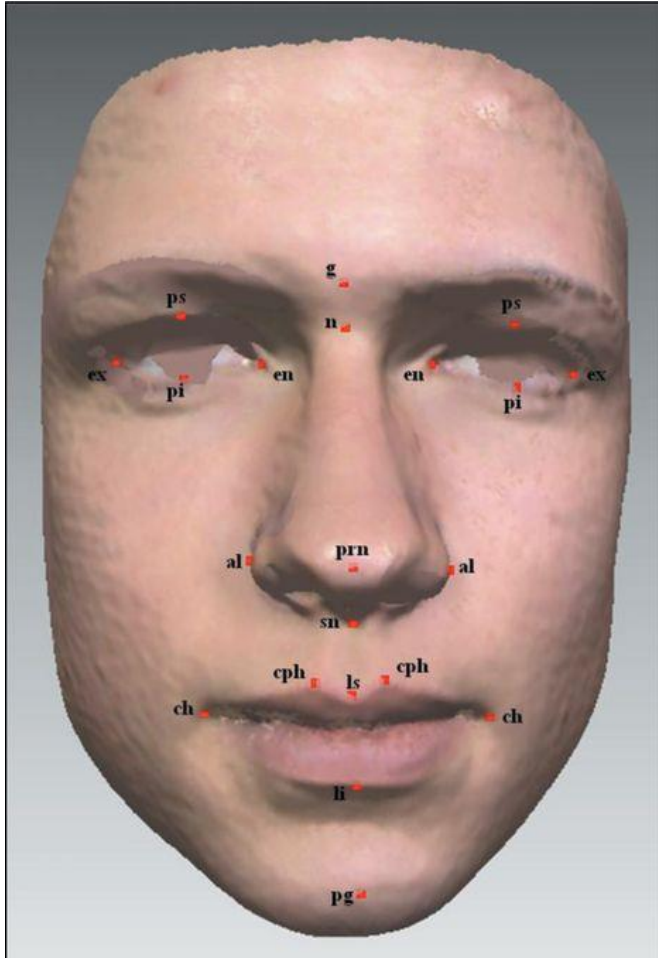


## Facial soft tissue landmarks.



- Glabella (g): Most prominent midline point between the eyebrows
- Nasion (n): Deepest point of nasal bridge
- Endocanthion (en) L/R: Inner commissure of the left and right eye fissure
- Exocanthion(ex) L/R: Outer commissure of the left and right eye fissure
- Palpebrale superius (ps) L/R: Superior mid-portion of the free margin of upper left and right eyelid
- Palpebrale inferius (pi) L/R: Inferior mid-portion of the free margin of upper left and right eyelid
- Pronasale (prn): Most protruded point of the apex nasi
- Subnasale (sn): Midpoint of angle at columella base
- Alare (al) L/R: Most lateral point on left and right alar contour
- Labiale superius (ls): Mid-point of the upper vermilion line
- Labiale inferius (li) L/R: Mid-point of the lower vermilion line
- Crista philtri (cph) L/R: Point on right elevated margin of the philtrum just above the vermilion line
- Cheilion (ch) L/R: Point located at left and right labial commissure
- Pogonion (pg) L/R: Most anterior mid-point of the chin

Ala Al Ali et al. Eur J Orthod 2014;36:506-511