

Online Research @ Cardiff

This is an Open Access document downloaded from ORCA, Cardiff University's institutional repository: <http://orca.cf.ac.uk/102771/>

This is the author's version of a work that was submitted to / accepted for publication.

Citation for final published version:

O'Sullivan, Michael and Vann, Seralynne D. 2016. Amyloid imaging and Alzheimer's disease: the unsolved cases. *Brain: A Journal of Neurology* 139 (9) , pp. 2342-2344. 10.1093/brain/aww166 file

Publishers page: <http://dx.doi.org/10.1093/brain/aww166> <<http://dx.doi.org/10.1093/brain/aww166>>

Please note:

Changes made as a result of publishing processes such as copy-editing, formatting and page numbers may not be reflected in this version. For the definitive version of this publication, please refer to the published source. You are advised to consult the publisher's version if you wish to cite this paper.

This version is being made available in accordance with publisher policies. See <http://orca.cf.ac.uk/policies.html> for usage policies. Copyright and moral rights for publications made available in ORCA are retained by the copyright holders.



Amyloid Imaging and Alzheimer's disease: the Unsolved Cases

Michael J O'Sullivan¹ PhD, FRCP and Seralynne D. Vann², PhD

¹Dept of Basic and Clinical Neuroscience, Wohl Clinical Neuroscience Institute, King's College London, UK

²School of Psychology and Neuroscience and Mental Health Research Institute, Cardiff University, UK

Correspondence to:

Michael O'Sullivan

Wohl Clinical Neuroscience Institute, 5 Cutcombe Rd, London SE5 9RT

Mike.osullivan@kcl.ac.uk

Disclosures: none

Acknowledgements: MOS receives support from the Medical Research Council UK (MR/K022113/1). SDV is a Wellcome Trust Senior Research Fellow.

The use of advanced imaging technology in sport – international cricket is a good example – has eliminated some old uncertainties but also uncovered new ones that were previously unknown. For example, is it possible for a ball to strike a bat without creating a *hot spot* (local heating through friction detected by infra-red cameras)? The same issue of unearthing novel questions while addressing old ones might be true of the use of imaging technology in dementia. In this issue of *Brain*, Chételat and co-workers explore a new question that has emerged from the use of amyloid PET scans in the diagnosis of dementia: how to interpret negative scans in patients who have a clinical phenotype that seems classical for Alzheimer's disease (Chételat et al., 2016).

The authors assembled 40 cases with negative amyloid PET scans and a pre-test diagnosis of Alzheimer's disease from 4 well-established centres (Caen, Melbourne, Amsterdam and San Francisco). Twenty-one of these cases had a typical amnesic presentation. Comparison groups were constructed from amyloid PET-positive typical Alzheimer's disease cases and healthy volunteers confirmed to be amyloid PET-negative. Inevitably, some limitations arose from differences in procedures across centres. However, the authors developed and implemented a stringent approach to remove as much inconsistency as possible. Strengths of this multi-centre design included central blinded re-reading of all PET scans and verification of all clinical diagnoses by a pre-defined review process, based on site visits by two core diagnosticians. The principal advantage of a formalised and effective international collaboration was that the authors were able to assemble enough cases to shed some light on the nature and natural history of amyloid-negative cases thought *a priori* to have Alzheimer's disease.

One finding of the study, which is not a surprise, is that the presumptive diagnosis of Alzheimer's disease was not particularly resilient to a negative amyloid scan. In approximately two-thirds of cases, and all but one (94%) of non-amnesic cases, clinicians reviewed the clinical profile and decided that another diagnosis was more suitable (including frontotemporal lobar degenerations, Lewy body disease and corticobasal degeneration). These

data suggest that clinicians have great faith in amyloid PET scans. They underline, in a different way, the uncertainty of clinical diagnosis. It remains unknown whether the post-PET diagnoses were more or less accurate, because a final arbiter of diagnosis is missing. What we do know is that clinical diagnoses are labile, indicating a latent uncertainty, especially in individuals lacking a demonstrable and well-circumscribed amnesia as the core of their cognitive deficit.

The most intriguing patients were those in whom no better alternative diagnosis could be found after PET, a group that came to be labelled as '*amnesic amyloid-negative unchanged*'. The authors identified 11 such cases and were able to sketch a clinical and radiological picture of this entity. In the supplementary material (Table S4) they provide case-by-case descriptions, a refreshing variation from a literature that is often rich on imaging detail but light on clinical description. As a group, these cases demonstrated subtle atrophy and hypometabolism of the posterior cingulate region (Figure 3 of the paper), features which are among the earliest changes to emerge in incipient Alzheimer's disease (Nestor et al. 2003, Pengas et al. 2010), but they lacked the more widespread neocortical alterations of typical amyloid-positive cases.

The key question, beyond the reach of this study, is what these alterations in the posterior cingulate region represent pathologically. One particular speculation of Chételat *et al.* revolves around neuropathological descriptions of Alzheimer's disease cases in which tau-related pathology predominates and amyloid plaques are sparse. An interesting recent observation, which supports this view, comes from a single case of a patient with a *presenilin-1* mutation, imaged with both amyloid and tau PET tracers (Figure 1, Smith et al. 2016). In this case, tau tracer uptake was strongly localised to midline posterior regions in a pattern closely matching that of hypometabolism. The spatial relationship between amyloid tracer binding and metabolism was less consistent. Chételat *et al.* correctly point out that visualisation of tau could provide greater diagnostic certainty. Another detail not to lose sight of is the exact binding target of amyloid tracers in the brain. Both Pittsburgh Compound B and Florbetapir, as used here, bind predominantly to β -pleated

sheet structures and are therefore not generic amyloid ligands but rather ligands for insoluble amyloid aggregates. One possibility is that amyloid 'positive' and 'negative' cases differ in the processing of amyloid downstream of soluble oligomers and non-fibrillar forms that are nevertheless neurotoxic (leading to what might be viewed as 'false negatives'). Of the 21 amnesic amyloid-negative cases identified prior to PET, 14 were female and 15 did not carry an apolipoprotein E4 allele, in contrast to typical amyloid-positive cases. Apolipoprotein E4 is known to have an effect on the deposition of fibrillar insoluble amyloid (Schmechel et al. 1993) of the sort that is avidly bound by amyloid tracers.

One reason that tau or soluble amyloid interpretations are so often put forward, and are so intuitively appealing, is that they fit within traditional boundaries: they demand no interrogation of our conceptual model of Alzheimer's disease. However, the real answer might not be so orthodox. The retrosplenial cortex, which lies within the atrophied and hypometabolic region described by Chételat and co-workers, is involved in episodic memory, navigation, imagination and planning for the future (Vann et al. 2009). Any pathology that affects this region might be expected to produce a clinical picture that overlaps with typical amnesic Alzheimer's disease. Isolated vascular lesions of this region are rare but have been associated with an amnesic syndrome (Valenstein et al. 1987). The extent of involvement of the retrosplenial cortex or its connections in more diffuse vascular disease is not known. Furthermore, alterations in this region are found in schizophrenia, bipolar disorder, post-traumatic stress disorder and dyslexia. The retrosplenial cortex also appears to be particularly sensitive to remote damage. In both patients and animal models, lesions of the hippocampus and medial diencephalon cause retrosplenial hypoactivity (Vann et al. 2009), which does not simply reflect the deafferentation of the retrosplenial cortex. As such, retrosplenial dysfunction appears to be a reliable sentinel marker of pathology within the hippocampal-thalamic network (Figure 2). It is possible that the amyloid-negative group is a collection of diverse mimics of amnesic Alzheimer's disease, connected by the common feature of retrosplenial/posterior cingulate regional dysfunction. The fact that many followed a

subsequent progressive course implies neurodegenerative disease, rather than other types of mimic. However, the authors rightly emphasise the heterogeneous natural history of amyloid-negative cases.

Correlation with post mortem diagnosis is an obvious way to shed more light on the subgroups, and transitions between diagnostic groups, described by Chételat *et al.* However, it is not the only way forward. Atrophy and hypometabolism are relatively blunt measures of structure and function. Investigation of cingulate connections and patterns of connectivity would deepen our understanding of the alterations in this broad region, particularly as it harbours subregions with quite different connectivity profiles (Morris *et al.*, 1999; Aggleton *et al.*, 2012). Functional studies are also important. Leech and Sharp described, from a synthesis of previous functional studies, how subregions relate differentially to the default modes of brain function, salience, attention and cognitive control, with a putative role for the posterior cingulate cortex in tuning network dynamics (Leech and Sharp 2014). The results of Chételat *et al.* also suggest scope for further neuropsychological investigation.

One challenge that arose during the review of Chételat *et al.* paper was what the 'amnesic amyloid-negative unchanged' group should be called – should they be called 'amyloid-negative Alzheimer's disease' (a pragmatic use of clinical criteria, an oxymoron, or too uncertain to be either)? Diagnostic labels have a natural life cycle. In some cases, as the field of knowledge expands, it becomes increasingly hard to place the original meaning of a term. Biomarker data can add support to a diagnostic label but can also unveil hidden contradictions. Imaging has added a dimension to the diagnostic space that was not present when many diagnostic labels were coined. We will never know the amyloid-PET status of Alois Alzheimer's cases. Labels eventually sink, weighed down by the debate around their precise modern meaning, which comes to outweigh the buoyancy of their advantages in classifying the diagnostic space. 'Binswanger's disease' is one example of a term that now lies on the ocean floor (Hachinski 1991). The implications of PET tracer studies for the lexicon surrounding common Alzheimer-like dementias will depend on further investigation and the knowledge that ensues. However, any

hope that amyloid imaging would lead to simple distinctions between Alzheimer's disease and non-Alzheimer dementias looks forlorn: it is not inevitable that new techniques will simplify disease nosology. As a modern cricketer would now tell you, technology brings new yet limited clarity; we should embrace it, but not expect it to end controversy.

Figure Legends

Figure 1. Posterior tau tracer binding co-localised with hypometabolism in a 38-year-old man with a *presenilin-1* mutation.

Imaging was performed with a tracer for insoluble amyloid (18F-Flumetamol, far left column) and a tau tracer (18F-AV-1451, second column). The strongest tau tracer binding is seen in posterior midline regions including the posterior cingulate cortex. Part of this region corresponds very closely to a sharply-defined area of hypometabolism. The implication is that even if amyloid were sparse, posterior cingulate hypometabolism would be seen in association with tau (Reprinted from Smith et al. *Journal of Alzheimer's Disease*, with permission from IOP Press. The publication is available at IOP Press through <http://dx.doi.org/10.3233/JAD-151004>).

Figure 2. The retrosplenial cortex as a sentinel for damage elsewhere in the hippocampal-thalamic network.

Reduced expression of the immediate-early gene, *c-fos*, in the rat retrosplenial cortex following a bilateral mammillothalamic tract (MTT) lesion (*right*) compared to a control animal (*left*). *c-fos* is considered a marker of neuronal activity, so reduced expression would indicate hypofunctionality of the retrosplenial cortex. The lesions only indirectly disconnect the retrosplenial cortex, so changes in immediate early gene expression are not due simply to deafferentation.

References

Aggleton JP, Wright NF, Vann SD, Saunders RC. Medial temporal lobe projections to the retrosplenial cortex of the macaque monkey. *Hippocampus* 2012; 22:1883-1900.

Chetelat G, Ossenkoppele R, Villemagne V, et al. Atrophy, hypometabolism and clinical trajectories in amyloid-negative Alzheimer's disease patients. *Brain* (this issue)

Hachinski V. Binswanger's disease: neither Binswanger's nor a disease. *J Neurol Sci* 1991;103:1

Leech R, Sharp DJ. The role of the posterior cingulate cortex in cognition and disease. *Brain* 2014;137:12-32.

Morris R, Petrides M, Pandya DN. Architecture and connections of retrosplenial area 30 in the rhesus monkey (*Macaca mulatta*). *Eur J Neurosci*. 1999;11:2506–2518.

Nestor PJ, Fryer TD, Smielewski P, Hodges JR. Limbic hypometabolism in Alzheimer's disease and mild cognitive impairment. *Ann Neurol* 2003;54:343-51.

Pengas G, Hodges JR, Watson P, Nestor PJ. Focal posterior cingulate atrophy in incipient Alzheimer's disease. *Neurobiol Aging* 2010;31:25-33.

Schmechel DE, Saunders AM, Strittmatter WJ, et al. Increased amyloid β -peptide deposition in cerebral cortex as a consequence of apolipoprotein E genotype in late-onset Alzheimer disease. *Proc Natl Acad Sci USA* 1993;90:9649-9653.

Smith R, Wibom M, Olsson T, Hägerström D, Jögi J, Rabinovici GD, Hansson O. Posterior Accumulation of Tau and Concordant Hypometabolism in an

Early-Onset Alzheimer's Disease Patient with Presenilin-1 Mutation. *J Alzheimers Dis* 2016;51:339-43.

Valenstein E, Bowers D, Verfaellie M, Heilman KM, Day A, Watson RT. Retrosplenial amnesia. *Brain* 1987;110:1631-46.

Vann SD, Aggleton JP, Maguire EA. What does the retrosplenial cortex do? *Nat Rev Neurosci* 2009;10:792-802.

Figure 1

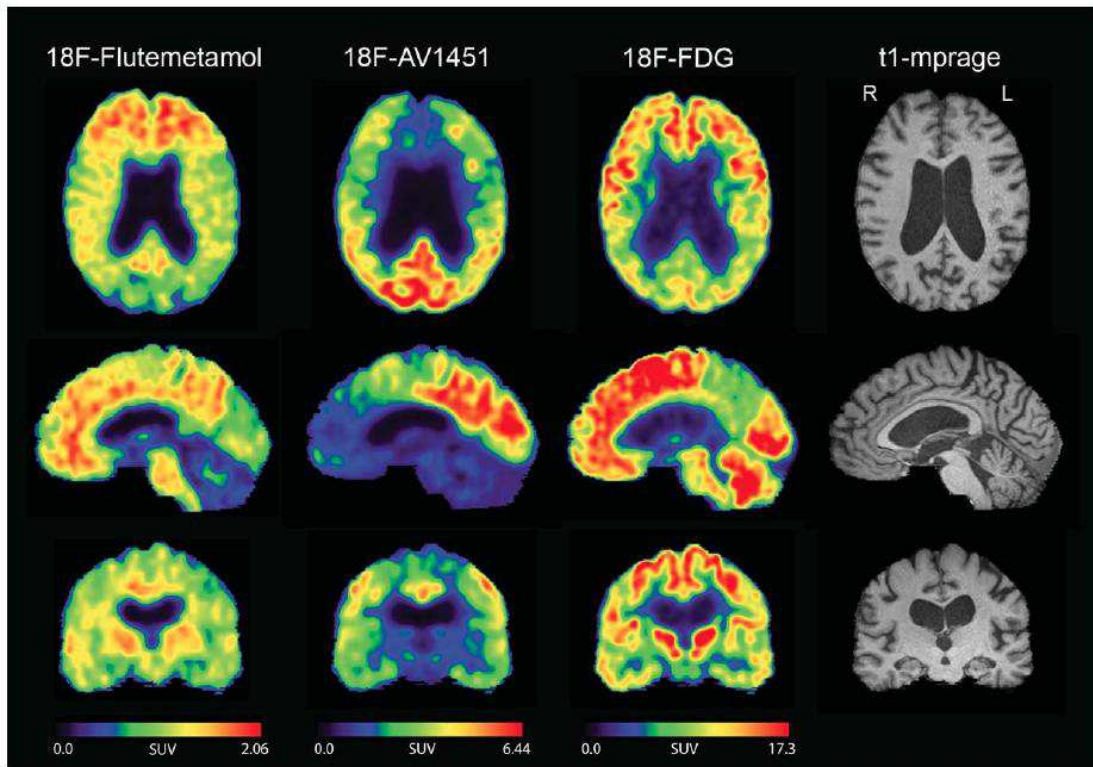


Figure 2

